



The protocol of low-impact laparoscopic cholecystectomy: the combination of mini-laparoscopy and low-pressure pneumoperitoneum

Nicola de'Angelis¹ · Niccoló Petrucciani¹ · Giusy Giannandrea¹ · Francesco Brunetti¹

Received: 17 February 2018 / Accepted: 24 August 2018
© Italian Society of Surgery (SIC) 2018

Abstract

Low-impact laparoscopic (LIL) cholecystectomy is an innovative surgical protocol that combines the use of mini-laparoscopic instruments (3-mm ports) under a low- and stable-pressure pneumoperitoneum (8 mmHg), with the aim of minimizing the surgical invasiveness and the risks related to CO₂ insufflation on the peritoneal environment. In day-surgery settings, LIL may contribute to increase the surgical success due to several potential benefits in terms of postoperative pain intensity and time to full recovery. In 14 consecutive patients requiring cholecystectomy for uncomplicated cholelithiasis, LIL was carried out uneventfully. No conversion, intra-operative or postoperative complications occurred. All patients were discharged the same day of surgery. **Postoperative pain was well tolerated with no need of prolonged opioid therapy.** Technical aspects and indications for LIL cholecystectomy are detailed.

Keywords Low-impact laparoscopy · Mini-laparoscopy · Cholecystectomy · Day surgery · Low-pressure pneumoperitoneum

Introduction

Laparoscopic cholecystectomy (LC) is one of the most performed surgical procedures worldwide, with more than 750,000 LCs each year in the United States [1]. Although laparoscopy is considered the gold standard surgical approach for the treatment of gallstone diseases, it remains associated with a high use of analgesics, especially opioids, in the postoperative period [2]. Indeed, technical efforts have been made to reduce surgical stress, postoperative morbidity, and postoperative pain to improve patient's comfort, minimize the need of analgesics, accelerate the return to normal activities, and enhance the success rate of day-surgery procedures while reducing healthcare-related costs.

The use of mini-laparoscopy (via 3 mm ports) was introduced to obtain such objectives. In particular, mini-laparoscopic cholecystectomy (MLC) was shown to be safe and

feasible with lower postoperative pain and better cosmetic results than LC, without impacting on the overall costs [3, 4]. To further minimize surgical stress and postoperative pain, a protocol of low-impact laparoscopy (LIL) combining the use of mini-laparoscopic instruments under a low- and stable-pressure pneumoperitoneum (8 mmHg) was recently evaluated in a sample of patients with sickle cell disease [5]. The interest of this innovative protocol is the combination of a minimally invasive surgical access with minimized risks related to CO₂ insufflation on the surgical peritoneal environment, which translate in several potential benefits in terms of intensity of postoperative pain and time to full recovery [6–8] (Fig. 1). Herein, we describe the technical aspects of LIL cholecystectomy and we discuss the indications for the general population.

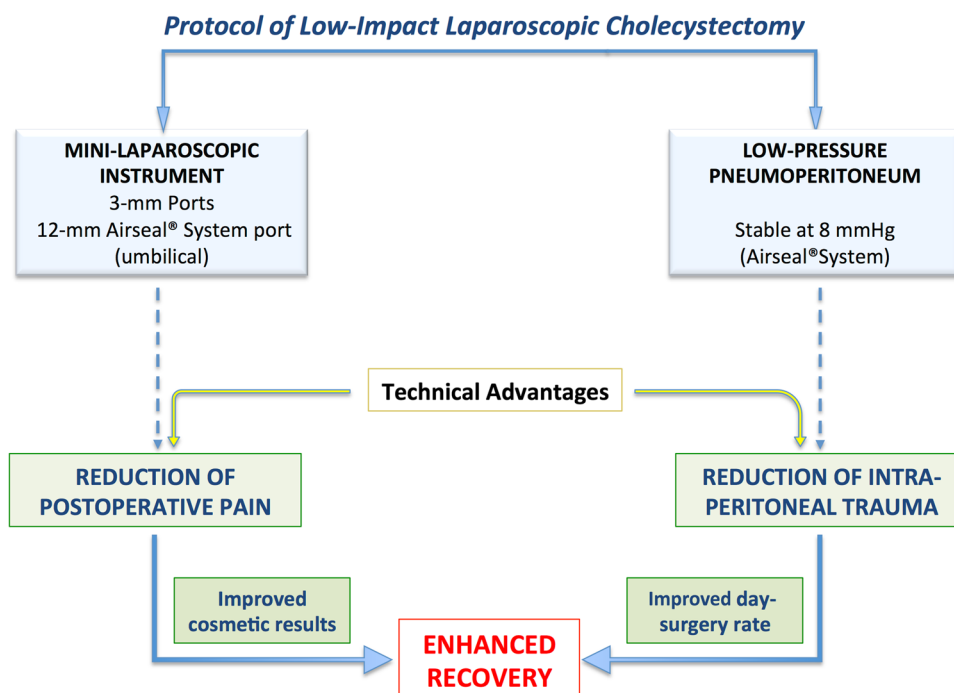
Methods

Adult patients with uncomplicated gallstone disease requiring surgery were candidate for day-surgery LIL cholecystectomy. Standard protocols for pre-operative and postoperative cares were followed. Patients were discharged after a minimum of 4 h from surgery following the re-evaluation

✉ Nicola de'Angelis
nicola.deangelis@aphp.fr

¹ Department of Digestive, Hepato-Pancreato-Biliary Surgery, and Liver Transplantation, Henri Mondor Hospital, AP-HP, University of Paris Est-UPEC, 51, Avenue du Maréchal de Lattre de Tassigny, 94010 Créteil, France

Fig. 1 Protocol of low-impact laparoscopic cholecystectomy



of the surgeon and anesthesiologist, and if no complication occurred and pain was well controlled. On the first postoperative day, Paracetamol was administered systematically to all patients (1 g, tid). At discharge, patients were also given a package of analgesics (paracetamol, 1 g) for 5 days with all information regarding the expected recovery pattern. Patients were advised that whether pain was too intense or not tolerated, opioids (e.g., tramadol) could be required. Within 24 h, all patients were contacted by telephone to check on their pain management and recovery progress. Reassessment was performed 30 days after surgery.

Technical notes

The patient is placed in supine reverse Trendelenburg position with the left arm abducted; the operating surgeon is standing between the patient's legs and the assistant surgeon at the patient's left. The 12-mm Airseal® (Conmed Corp, Utica, NY, USA) port is inserted using an open trans-umbilical technique. A low-pressure pneumoperitoneum is established at 8 mmHg and maintained stable by Airseal® System. Then, three 3-mm ports (ABmedica s.a.s, Mery-sur-Cher, France) are placed in the epigastric, left hypochondriac, and right hypochondriac regions, as shown in Fig. 2, under visual control using a 10-mm optical device. Whether port-positioning results difficult, the intra-peritoneal pressure may be temporarily increased at 10 mmHg to gather a better visualization of the surgical field and achieve an optimal port placement.

Calot's triangle is dissected with bipolar forceps and scissors. The cystic duct and artery are identified. At this time, a 3-mm optical device is connected to the camera and inserted in the left hypochondriac port. Clips (10-mm absorbable clips, Laproclip, Covidien, Dublin, Ireland) are placed through the Airseal port on the cystic duct and artery. Then, the 10-mm optical device is reconnected to the camera and inserted in the Airseal port, and the cystic duct and artery are cut using 3-mm scissors. Dissection of the gallbladder from the liver is performed. An endo-bag is inserted through the Airseal port for removal of the gallbladder. If necessary, a 3-mm suction device may be used. The fascial defect at the umbilicus is closed with interrupted polydioxanone absorbable sutures, and the peri-umbilical skin incision is sutured with a running absorbable suture. The mini-laparoscopic skin incisions are closed with simple adhesives.

Results

Between September 2017 and December 2017, 14 patients underwent elective day-surgery LIL for uncomplicated cholelithiasis. Clinical, operative, and postoperative variables are summarized in Table 1. Eleven patients (78.6%) experienced at least one episode of cholecystitis prior to surgery, which was performed after an 8-week asymptomatic period. No conversion to standard laparoscopy or laparotomy occurred. No intra-operative or postoperative complications were recorded. All patients were discharged the same day of surgery. Postoperative pain was well tolerated; only

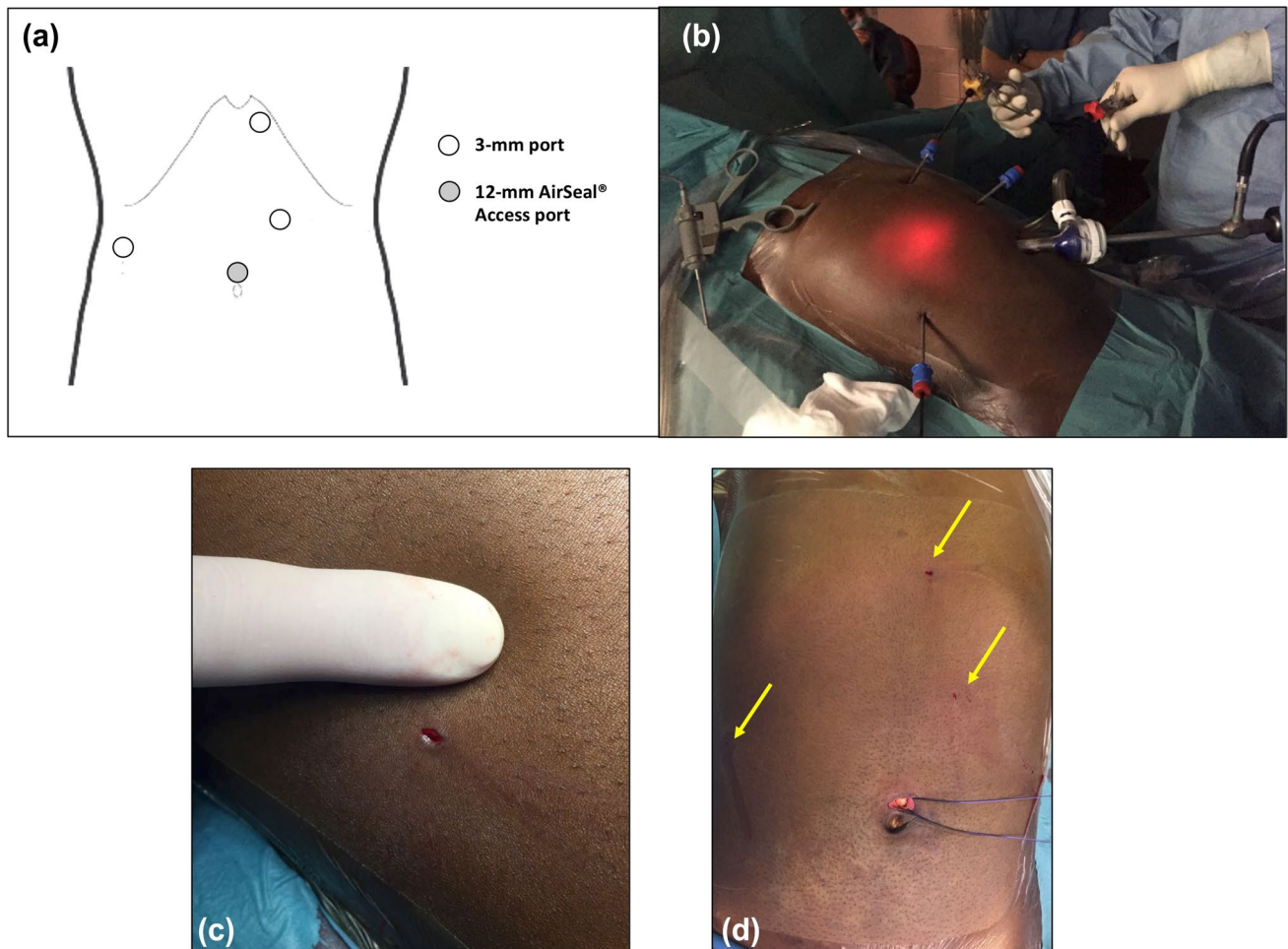


Fig. 2 Mini-laparoscopic port incision and positioning: **a** schematic representation; **b** operative picture; **c** 3 mm size incision; **d** all 3-mm port incisions plus 12-mm umbilical port incision

one patient required opioids in the first week after surgery. No prolonged opioid therapy was needed.

Discussion

Reduction of the surgical stress is one of the main objectives of modern minimally invasive surgery. LIL was defined as the surgical technique that combines miniaturized surgical instruments with 8 mmHg-pressure pneumoperitoneum, which contribute together to reduce the surgical invasiveness, the parietal stress, the barotrauma and, consequently, the risk of postoperative complications or intense pain [6–8]. Furthermore, the application of this protocol can enhance the success rate of day surgery, which depends on the quality of surgery and recovery.

Indeed, LC is most of the time performed as a day-surgery procedure. After day case LC, postoperative pain represents the main reason for patient readmission (accounting

for 45.5% of all readmissions), followed by wound infection (22.7%) [9]. A suboptimal pain management in the post-operative period is a reason for patients to postpone work resumption, seeking for medical consultations and drug prescriptions. Indeed, the incidence of persistent opioid use after minor surgery, also in opioid naive patients, is not negligible and it represents a rarely appreciated marker of surgical quality [2, 10]. By applying a low-impact laparoscopic cholecystectomy, no patient developed pain related complications (e.g., shoulder pain), or required prolonged opioid therapy.

Furthermore, this technique provides excellent cosmetic results that increase patient's satisfaction compared to standard laparoscopy [5]. However, a specific training may be required to become proficient with the 3-mm surgical instrumentation used under 8-mm pneumoperitoneum. No knowledge so far on the learning curve, but it must be noted that port positioning and procedural steps are the same for MLC than LC. Thus, it could be assumed that, after a reasonable

Table 1 Demographic, clinical, operative, and postoperative characteristics of patients operated on by low-impact laparoscopic (LIL) cholecystectomy ($n = 14$)

Variables	$N = 14$
Gender (F/M) [n]	9/5
Age (year) [median (range)]	49 (22–60)
BMI (kg/m ²) [median (range)]	30.5 (26–32)
Obesity (BMI ≥ 30 kg/m ²) [n (%)]	3 (21.4)
ASA score I/II/III [n]	2/9/3
Cardio-pulmonary diseases [n (%)]	3 (21.4)
Kidney diseases [n (%)]	1 (7.1)
Liver diseases [n (%)]	2 (14.3)
Pre-operative leukocytes (10 ⁹ /L) [mean (SD)]	8.01 (1.86)
Pre-operative alanine aminotransferase > 40 U/L [n (%)]	5 (35.7)
Pre-operative aspartate aminotransferase > 40 U/L [n (%)]	3 (21.4)
Previous upper abdominal surgery [n (%)]	7 (50)
Indication for surgery [n (%)]	
Asymptomatic cholelithiasis	1 (7.1)
Biliary colic	2 (14.3)
Antecedent cholecystitis	11 (78.6)
Operative time (min) [mean (SD)]	59 (7.2)
Need of additional port (one 5-mm port) [n (%)]	0
Conversion [n (%)]	
To laparotomy	0
To standard laparoscopy	0
Failure to maintain low-pressure pneumoperitoneum (at 8-mmHg) [n (%)]	0
Accidental opening of gallbladder [n (%)]	1 (7.1)
Operative blood loss (mL) [median (range)]	0 (0–50)
Patients with postoperative complications [n (%)]	0
Reoperation need [n (%)]	0
Success rate of day surgery (%)	100
Readmission within 60 days [n (%)]	0
Opioid need within 30 days [n (%)]	1 (7.1)

BMI body mass index, ASA American Society of Anesthesiology

training phase, the surgeon expert in minimally invasive surgery will not experience major difficulties in applying LIL cholecystectomy [4, 5].

Author contributions Study conception and design: NA and FB. Acquisition of the data: NA, NP, GG, and FB. Analysis and interpretation of data: NA, NP, and FB. Drafting of manuscript: NA and NP. Critical revision of manuscript: NA, NP, GG, and FB.

Compliance with ethical standards

Conflict of interest The authors declare that they have no competing interests.

Research involving human participants and/or animals The present manuscript is in compliant with ethical standard. This study does not involve any kind of animal related contacts or experiments by any of the listed authors.

Informed consent All the patients included gave their informed consent.

References

1. “Characteristics of Operating Room Procedures in U.S. Hospitals, 2011-Statistical Brief #170”. 2011 [cited 2018 24 January]
2. Brummett CM, Waljee JF, Goesling J, Moser S, Lin P, Englesbe MJ, Bohnert ASB, Kheterpal S, Nallamothu BK (2017) New persistent opioid use after minor and major surgical procedures in US adults. *JAMA Surg* 152(6):e170504
3. Alhashemi M, Almahroos M, Fiore JF Jr, Kaneva P, Gutierrez JM, Neville A, Vassiliou MC, Fried GM, Feldman LS (2017) Impact of miniport laparoscopic cholecystectomy versus standard port laparoscopic cholecystectomy on recovery of physical activity: a randomized trial. *Surg Endosc* 31(5):2299–2309
4. Dammaro C, Tranchart H, Gaillard M, Debelmas A, Ferretti S, Lainas P, Dagher I (2017) Routine mini-laparoscopic cholecystectomy: outcome in 200 patients. *J Visc Surg* 154(2):73–77
5. de’Angelis N, Abdalla S, Carra MC, Lizzi V, Martinez-Perez A, Habibi A, Bartolucci P, Galacteros F, Laurent A, Brunetti F (2018) Low-impact laparoscopic cholecystectomy is associated with decreased postoperative morbidity in patients with sickle cell disease. *Surg Endosc* 32(5):2300–2311. <https://doi.org/10.1007/s00464-017-5925-y>
6. Gurusamy KS, Samraj K, Davidson BR (2009) Low pressure versus standard pressure pneumoperitoneum in laparoscopic cholecystectomy. *Cochrane Database Syst Rev*. <https://doi.org/10.1002/14651858.CD006930.pub2>
7. Matsuzaki S, Vernis L, Bonnin M, Houle C, Fournet-Fayard A, Rosano G, Lafaye AL, Chartier C, Barriere A, Storme B, Bazin JE, Canis M, Botchorishvili R (2017) Effects of low intraperitoneal pressure and a warmed, humidified carbon dioxide gas in laparoscopic surgery: a randomized clinical trial. *Sci Rep* 7(1):11287
8. Neudecker J, Sauerland S, Neugebauer E, Bergamaschi R, Bonjer HJ, Cuschieri A, Fuchs KH, Jacobi C, Jansen FW, Koivusalo AM, Lacy A, McMahon MJ, Millat B, Schwenk W (2002) The European Association for Endoscopic Surgery clinical practice guideline on the pneumoperitoneum for laparoscopic surgery. *Surg Endosc* 16(7):1121–1143
9. Awolaran O, Gana T, Samuel N, Oaikhinan K (2017) Readmissions after laparoscopic cholecystectomy in a UK District General Hospital. *Surg Endosc* 31(9):3534–3538
10. Brat GA, Agniel D, Beam A, Yorkgitis B, Bicket M, Homer M, Fox KP, Knecht DB, McMahill-Walraven CN, Palmer N, Kohane I (2018) Postsurgical prescriptions for opioid naive patients and association with overdose and misuse: retrospective cohort study. *BMJ* 360:j5790